

Letters

OBSERVATION

Unusual Presentation of Poppers Dermatitis

Cutaneous adverse effects of alkyl nitrites (“poppers”) are underestimated because the drug is generally used as an inhalant. Poppers can cause irritant or allergic contact dermatitis, especially on the face, with exceptional cases in other areas of the body.¹⁻³ We report a unique case of an ulcer of the penis secondary to poppers toxic effects in a homosexual man, highlighting the importance of including exogenous chemical agents in the differential diagnosis of genital ulcers in men who have sex with men (MSM).

Report of a Case | A homosexual man presented with an ulcerative lesion on his penis of 2 months’ duration. He had consulted several dermatologists and received different local and systemic treatments including with antibiotics, steroids, and antimycotic drugs, with no improvement. The man had a stable partner and denied both casual and unprotected sex as well as the use of creams or balms on the penis.

On examination, the shaft of the penis had an asymptomatic, oval ulcer of more than 3 cm on its long axis with undermined borders and a sanious reddish bottom (**Figure 1**). The patient underwent serological antibody screening for syphilis and human immunodeficiency virus (HIV); microbiological screening for the presence of common bacteria and yeasts; and polymerase chain reaction testing for the presence of *Treponema* and *Chlamydia* species, all with negative results. Histologic analysis of the ulcer border showed full epidermal necrosis with infiltration of neutrophils and eosinophils. A diffuse dermal inflammatory infiltrate rich in polymorphonuclear cells, and focal fibrinoid necrosis of superficial vessels were also seen (**Figure 2**).

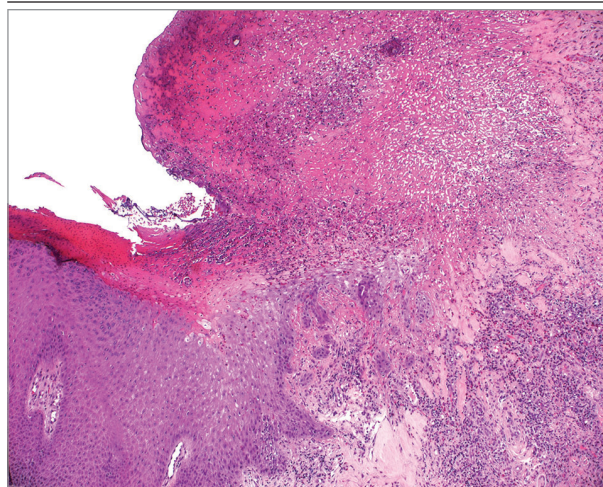
The patient underwent counseling with a psychologist to investigate his personality and a possible diagnosis of artifact dermatitis. He was asked about his sexual behaviors and about use of sex toys or drugs. The patient reported using a popper called “Jungle Juice” during his sexual encounters, and he could not rule out accidental contact between his contaminated hands and his genitals. Results of patch testing using an International Contact Dermatitis Research Group standard series and a single patch test with alkyl nitrite preparation at 2% in water were negative at 48 and 72 hours. A final diagnosis of irritant (popper) contact dermatitis was made.

Discussion | *Poppers* is a generic term for volatile substances belonging to the alkyl nitrite chemical family. The chemical has vasodilatory properties and relaxes smooth muscles. In the past, it was used in cardiology practice, but its use was discontinued owing to its toxic effects. Its use is illegal, but to bypass legal restrictions, alkyl nitrites are sold as liquid incense, room odorizer, or even leather cleaner. Poppers are widely used in the MSM

Figure 1. Asymptomatic Undermined Oval Ulcer of the Shaft of the Penis

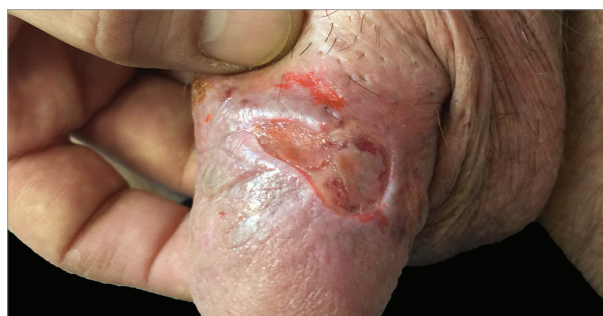

Figure 2. Lesional Histologic Specimen



Full-thickness necrosis of the epidermis is seen with a collection of eosinophils and neutrophils associated with a diffuse inflammatory infiltrate of the dermis (hematoxylin-eosin, original magnification $\times 100$).

community for their ability to relax the anal sphincter and for their psychoactive effects. Hematological, neurological, and particularly ocular adverse effects of poppers have been increasingly reported.^{4,5} In the skin, they induce irritant or allergic contact reactions, mainly reported on the face. Poppers dermatitis in sites other than the face is rare and may represent a diagnostic challenge for clinicians, especially since patients might not freely admit to using them.² In addition, accidental contact cannot be recognized by the patient, making the correct diagnosis impossible. Therefore, the presence of noninfectious skin ulcers in a homosexual man should be investigated for particular sexual behaviors and for recreational drug use.

Recreational drug use is associated with a reduced perception of risk of sexually transmitted diseases, including HIV, and has been linked to increased practice of unprotected sex among MSM.⁶ Accordingly, our case highlights the role of poppers in skin and mucous membrane integrity loss by making

the MSM more vulnerable to sexually transmitted infections as syphilis, chlamydia, hepatitis C, and HIV. A high level of attention and a multidisciplinary approach is essential in particular cases of genital ulcer to identify relevant sexual behaviors and consequent diseases.

Alessandra Latini, MD
Viviana Lora, MD
Mauro Zaccarelli, MD
Antonio Cristaudo, MD
Carlo Cota, MD

Author Affiliations: Dermatologic Infectious Diseases Unit, San Gallicano Dermatological Institute, Rome, Italy (Latini, Cristaudo); Dermopathology Unit, San Gallicano Dermatological Institute, Rome, Italy (Lora, Cota); Viral Immunodeficiency Unit, National Institute for Infectious Diseases "Lazzaro Spallanzani," Rome, Italy (Zaccarelli).

Corresponding Author: Carlo Cota, MD, Dermatopathology Unit, San Gallicano Dermatological Institute, Via Elio Chianesi 53, 00144 Rome, Italy (cota@ifio.it).

Published Online: December 7, 2016. doi:10.1001/jamadermatol.2016.4262

Conflict of Interest Disclosures: None reported.

Additional Contributions: We are indebted to Marco Gentile, MD, for clinical support. He received no compensation for his contributions.

1. Bos JD, Jansen FC, Timmer JG. Allergic contact dermatitis to amyl nitrite ('poppers'). *Contact Dermatitis*. 1985;12(2):109.
2. Schaubert J, Herzinger T. 'Poppers' dermatitis. *Clin Exp Dermatol*. 2012;37(5):587-588.
3. Foroozan M, Studer M, Splingard B, Cuny JF, Barbaud A, Schmutz JL. Facial dermatitis due to inhalation of Poppers [in French]. *Ann Dermatol Venerol*. 2009;136(3):298-299.
4. Reggad A, Ficko C, Andriamanantena D, Flateau C, Rapp C. Acute hemolytic anemia in an HIV patient after inhalation of amyl nitrite [in French]. *Med Mal Infect*. 2012;42(12):619-620.
5. Clemens CR, Alten F, Loos D, Uhlig CE, Heiduschka P, Eter N. Poppers maculopathy or retinopathy? *Eye (Lond)*. 2015;29(1):148-149.
6. Hunter LJ, Dargan PI, Benzie A, White JA, Wood DM. Recreational drug use in men who have sex with men (MSM) attending UK sexual health services is significantly higher than in non-MSM. *Postgrad Med J*. 2014;90(1061):133-138.